Intercostal Cryoneurolysis

Junjian Huang, MD[1] Kevin Delijani, BS[2] Husamuddin El Khudari, MD[1] Andrew J. Gunn, MD[1]

[1] Department of Radiology, University of Alabama at Birmingham, Birmingham, Alabama
[2] Georgetown University School of Medicine, Washington, District of Columbia

Address for correspondence Junjian Huang, MD, Department of Radiology, University of Alabama at Birmingham, Birmingham, AL 35294 (e-mail: JunjianHuang@uabmc.edu).

Semin Intervent Radiol 2022;39:167–171

Abstract

Chest wall pain affects many patients following chest surgery, fractures, or malignancies, and can be very difficult to manage with normal pharmacologic agents. Intercostal ablation provides one alternative treatment modality for patients suffering from intercostal pain. Intercostal cryoneurolysis involves using extreme cold to cause Wallerian degeneration of the targeted intercostal nerve. This article reviews the patient selection, technique, and complications in the utilization of intercostal neurolysis in the treatment of intractable chest pain.

Keywords
- intercostal cryoneurolysis
- nerve ablation
- interventional radiology
- pain management

Chest wall pain affects nearly 50% of patients following chest wall surgery.[1] The underlying conditions of chest wall pain are often difficult to manage, and the associated pain is often refractory to common therapies including nonsteroidal anti-inflammatory drugs, opioids (often leading to tolerance or side effects), gabapentin, and local or regional anesthesia. Intercostal ablation has emerged as a treatment modality for patients suffering from intercostal pain of various etiologies.[2–7] Intercostal cryoneurolysis (IC) involves using extreme cold to cause Wallerian degeneration of the targeted intercostal nerve. The intercostal nerves arise from the anterior spinal nerve root divisions of the anterior primary rami of T1–T12 to innervate the thoracic wall and parietal pleura.[8] Various conditions can result in intercostal neuralgia including chest wall surgery, fractures, malignancies, and essentially anything resulting in direct nerve injury or inflammation.

IC for chest wall pain has been associated with various degrees of decreased pain and narcotic utilization.[3] In addition, the therapy has demonstrated success in alleviating pain involving chest wall and upper abdominal pain secondary to malignancy,[6] intercostal neuralgia,[9] pectus excavatum repair,[4] and postthoracotomy pain syndrome.[10] Herein we provide a technical overview of how to perform intercostal block and cryoneurolysis as well as explore the various etiologies of chest wall pain for the utilization of IC in those spaces.

Intercostal Block and Neurolysis Technique

Intercostal blocks with local anesthetics can be effective for treating pain and can also be useful in determining if cryoneurolysis will be effective. History and physical exam are obtained starting with a description of where the pain is located and when it started, particularly if related to a previous intervention or traumatic event. Intercostal neuralgia can manifest in many ways but typically described as pain or sensations that track from the anterior chest toward the back along a rib or, if a lower intercostal nerve is involved, vague abdominal pain that tracks to the back (►**Fig. 1**).

Once the history and physical exam have been completed, the affected rib is marked with a purple marking pin to the angle of the rib and put "x" marks at that rib as well as the one above and below (three ribs). If the affected area spans two ribs, one rib above and below the region is marked (four ribs).

Intercostal Block Technique

Patients are positioned prone with the arm of the affected side placed above the head; this is to encourage splaying of the ribs. Under ultrasound guidance, a 25-gauge spinal needle is inserted through the skin with the tip of the needle placed into the subcostal groove located on the underside of the rib and just above the pleura. Under fluoroscopy, 0.5 to

Issue Theme Advanced Interventional Pain Management; Guest Editor, J. David Prologo, MD

© 2022. Thieme. All rights reserved.
Thieme Medical Publishers, Inc., 333 Seventh Avenue, 18th Floor, New York, NY 10001, USA

DOI https://doi.org/10.1055/s-0042-1745763.
ISSN 0739-9529.

This document was downloaded for personal use only. Unauthorized distribution is strictly prohibited.

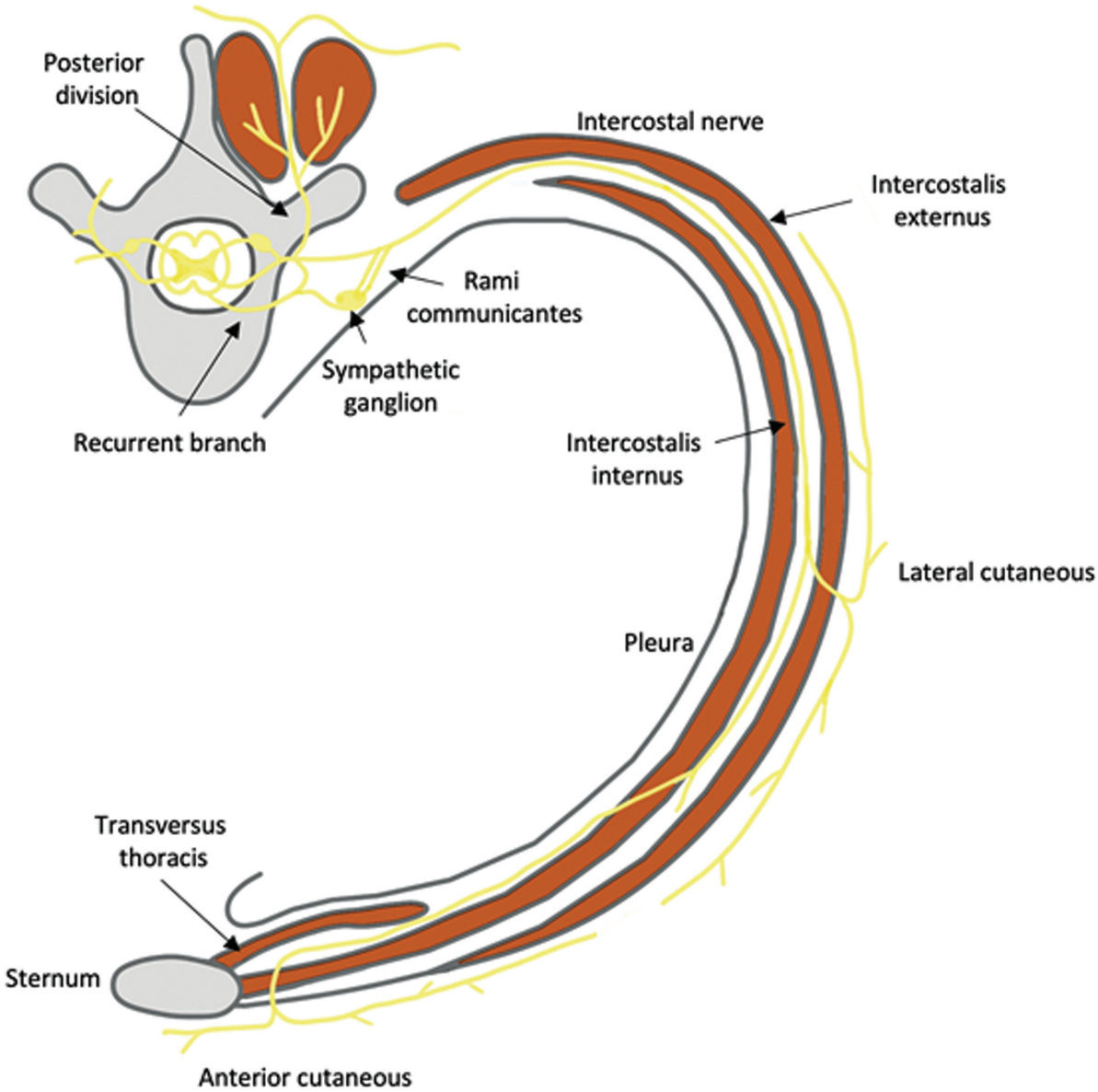

Fig. 1 Drawing of intercostal nerve anatomy.

1 mL of iodinated contrast is injected slowly with attention paid particularly for horizontal dispersion (►**Figs. 2** and **3**). Once confirmed, 3 mL of 0.25% bupivacaine is injected and this process is repeated for the other involved intercostal areas. These are performed without sedation or subcutaneous lidocaine to gain real-time feedback from the patient as it pertains to symptomatic relief. Analgesia may be given afterward for comfort if needed. A phone survey is conducted 48 to 72 hours later to evaluate pain improvement as well as gauge interest in proceeding with cryoneurolysis.

Intercostal Cryoneurolysis Technique

Percutaneous IC procedures are performed under CT guidance. Patients are positioned prone and placed under general anesthesia. IceSphere 1.5 (Boston Scientific, Boston, MA) cryoablation probes are placed in the intercostal space approximately 5 cm away from the neuroforamen and 5 mm from the subcostal groove to avoid vascular injury with the probe (►**Fig. 4**). Once probes are placed, two alternating freeze–thaw cycles are performed with the first cycle being an 8-minute ablation at 100% followed by a passive 3-minute thaw and the second cycle being a 3-minute ablation at 100% followed by a 3-minute passive thaw. The probes are removed at the end of the last 3 minute thaw. Intraoperative CT is performed at the end of each freeze cycle and following needle removal. The skin is protected from the cryoablation zones by blue towels soaked in warm saline.

Discussion

Postthoracotomy Pain

Nearly half of patients who undergo thoracotomy develop postthoracotomy chest pain. IC has demonstrated

 © 2022. Thieme. All rights reserved.

This document was downloaded for personal use only. Unauthorized distribution is strictly prohibited.

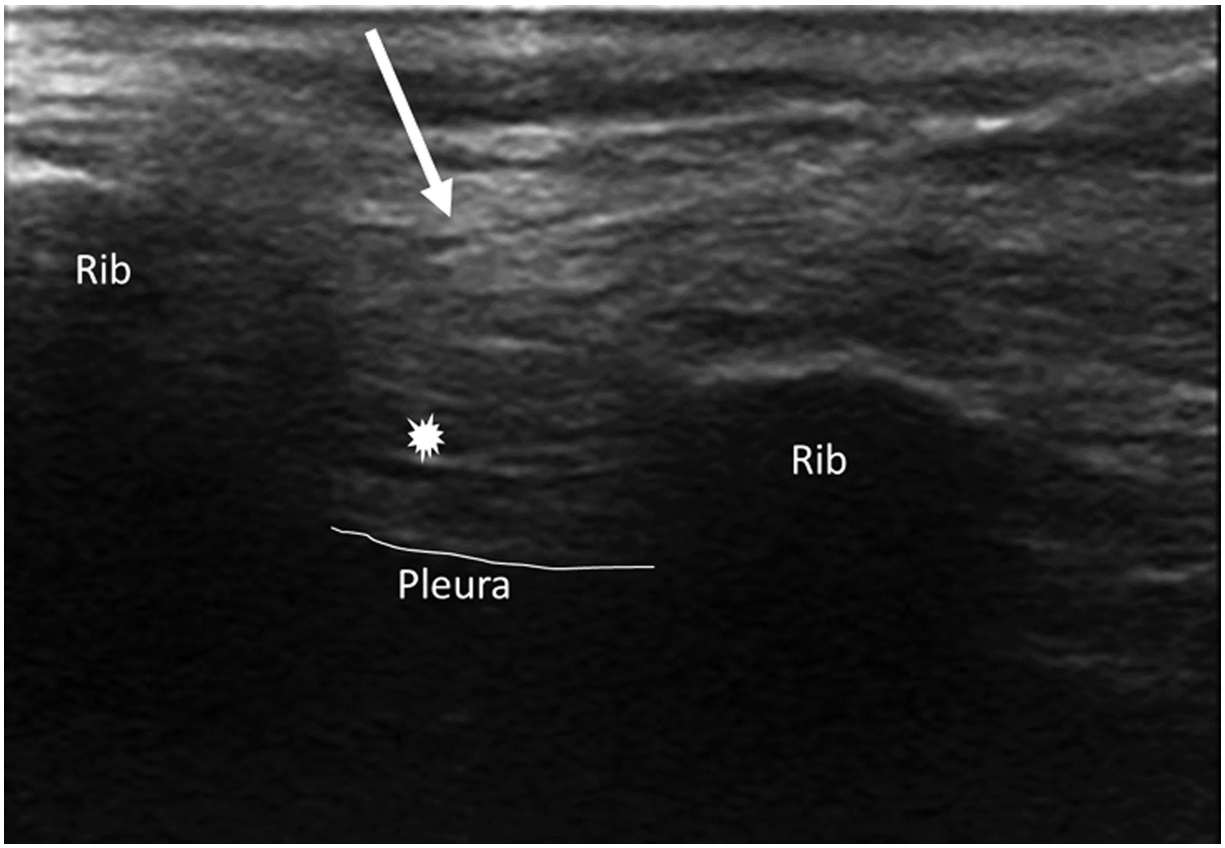

Fig. 2 Ultrasound-guided intercostal nerve block. A 25-gauge spinal needle (white arrow) is inserted with caudal to cranial angulation and then advanced into the subcostal groove. The asterisk (*) denotes the region of the intercostal nerve.

association with decreased narcotic utilization,[11–13] and decreased postoperative pain,[14,15] in the perioperative and early postoperative periods. Although most experiences with IC in this space were via nonrandomized control trials, a randomized control trial involving 24 individuals comparing cryotherapy to local anesthetics or no nerve block demonstrated significantly lower postoperative pain at 3 days.[14] IC has also demonstrated utility in patients who develop postthoracotomy pain syndrome, with pain scores decreasing to 3 to 6 points in two studies with a total of 31 adult patients.[10,16]

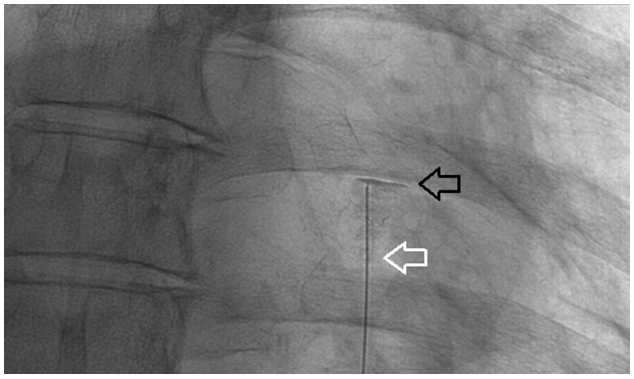

Fig. 3 Fluoroscopic image with contrast injection into the subcostal groove with subcostal spread of contrast (black arrow). White arrow—needle.

Trauma

Chest trauma is common and accounts for approximately 10% of patients admitted for injury.[17] Rib fractures are troublesome, as they can worsen acute pulmonary injuries both via physical displacement and through injury to the intercostal nerves. Additionally, rib fractures have been shown to cause significant chronic pain, morbidity, mortality, and extended prolonged disability.[18] Current interventional management of pain surrounding rib fractures is a mixture of surgical fixation and regional blocks including that of the intercostal nerve. Small retrospective case series have demonstrated an association between IC and improved pain and shortened time to extubation.[7,19]

Pectus Excavatum Repair

Pectus excavatum is one of the leading causes of chest wall deformity occurring 1 in 400 to 1 in 1,000 live births.[20] Typically, these are repaired in childhood using a bar inserted between the ribs and under the sternum to elevate and expand the chest wall cavity. These procedures utilize bilateral thoracotomies and patients are usually admitted postoperatively for pain control. IC has been demonstrated to reduce hospital length of stay by 2 to 3 days and some demonstrated decreased postprocedural narcotic utilization.[21–23]

 © 2022. Thieme. All rights reserved.

This document was downloaded for personal use only. Unauthorized distribution is strictly prohibited.

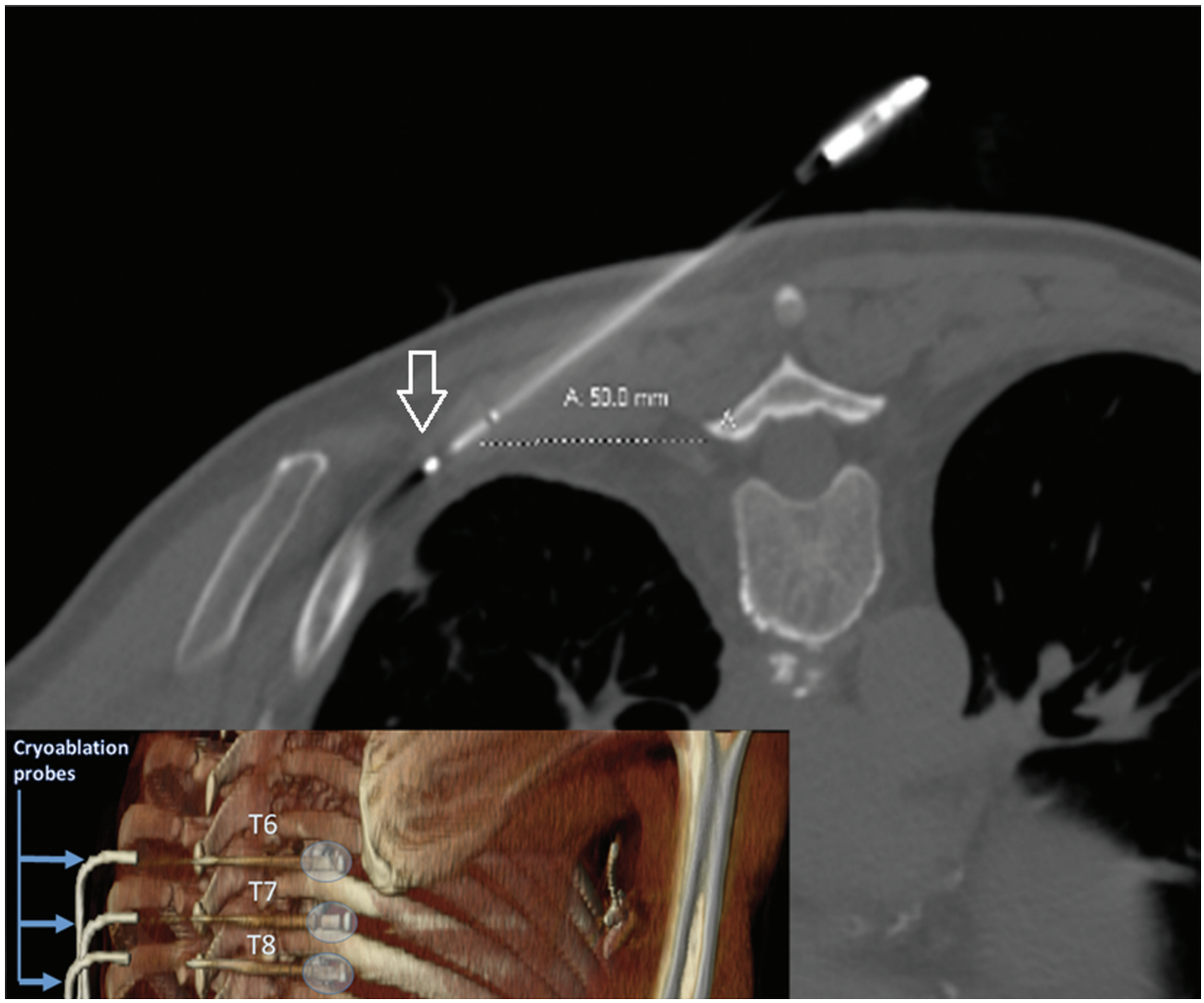

Fig. 4 Intraoperative axial computed tomographic image of probe placement. Note that the IceSphere 1.5 probe (arrow) is inserted in plane with the affected rib with ablation zone ~5 mm away from the subcostal groove and 5 cm away from the thoracic nerve roots. Multiplanar reconstruction of the CT demonstrates multiple probe positions.

Malignancy

Thoracic malignancy, whether primary or metastatic, can cause chest wall pain by involving the pleura, musculature, and osseous structures. IC can also be useful in the setting of refractory chest wall malignancy where it has been demonstrated to provide short-term relief of approximately 3 to 4 points on Numeric Rating Scale lasting 45 days on average.[6]

Complications

There have been very few major complications reported with IC with postoperative neuralgia being the most common. Isolated incidents of chest wall hematomas and pneumothorax with other potential complications include chest wall laxity and numbness with numbness.[24]

Conclusion

Intercostal cryoneurolysis is a safe and effective treatment for most causes of chest wall pain and should be considered as an adjunct for pain control.

Conflict of Interest
None declared.

References

1 Karmakar MK, Ho AM. Postthoracotomy pain syndrome. Thorac Surg Clin 2004;14(03):345–352
2 Saberski LR. Cryoneurolysis. In: Waldman SDB, ed. Pain Management: W.B. Saunders. 2007:1460–1474
3 Cha PI, Min JG, Patil A, Choi J, Kothary NN, Forrester JD. Efficacy of intercostal cryoneurolysis as an analgesic adjunct for chest wall pain after surgery or trauma: systematic review. Trauma Surg Acute Care Open 2021;6(01):e000690
4 Dekonenko C, Dorman RM, Duran Y, et al. Postoperative pain control modalities for pectus excavatum repair: a prospective observational study of cryoablation compared to results of a randomized trial of epidural vs patient-controlled analgesia. J Pediatr Surg 2020;55(08):1444–1447
5 Yang MK, Cho CH, Kim YC. The effects of cryoanalgesia combined with thoracic epidural analgesia in patients undergoing thoracotomy. Anaesthesia 2004;59(11):1073–1077
6 Daubié S, Pilleul F, Thivolet A, et al. Cryoneurolysis in patients with dorsal neuropathic pain secondary to tumor invasion. J Vasc Interv Radiol 2020;31(06):917–924

 © 2022. Thieme. All rights reserved.

This document was downloaded for personal use only. Unauthorized distribution is strictly prohibited.

7 Zhao F, Vossler J, Kaye A. A multi-institution case series of intercostal nerve cryoablation for pain control when used in conjunction with surgical stabilization of rib fractures. J Cardiothorac Trauma 2019;4:28
8 Netter FH. Thorax: lungs. In: Atlas of Human Anatomy. 2014. Accessed October 9, 2021 at: http://www.netteranatomy.com/anatomylab/subregions.cfm?subregionID=R34&contentDir=anatomylab/contents/region/t
9 Abd-Elsayed A, Lee S, Jackson M. Radiofrequency ablation for treating resistant intercostal neuralgia. Ochsner J 2018;18(01):91–93
10 Yasin J, Thimmappa N, Kaifi JT, et al. CT-guided cryoablation for post-thoracotomy pain syndrome: a retrospective analysis. Diagn Interv Radiol 2020;26(01):53–57
11 Nelson KM, Vincent RG, Bourke RS, et al. Intraoperative intercostal nerve freezing to prevent postthoracotomy pain. Ann Thorac Surg 1974;18(03):280–285
12 Glynn CJ, Lloyd JW, Barnard JD. Cryoanalgesia in the management of pain after thoracotomy. Thorax 1980;35(05):325–327
13 Brynitz S, Schrøder M. Intraoperative cryolysis of intercostal nerves in thoracic surgery. Scand J Thorac Cardiovasc Surg 1986;20(01):85–87
14 Katz J, Nelson W, Forest R, Bruce DL. Cryoanalgesia for post-thoracotomy pain. Lancet 1980;1(8167):512–513
15 Bucerius J, Metz S, Walther T, et al. Pain is significantly reduced by cryoablation therapy in patients with lateral minithoracotomy. Ann Thorac Surg 2000;70(03):1100–1104
16 Moore W, Kolnick D, Tan J, Yu HS. CT guided percutaneous cryoneurolysis for post thoracotomy pain syndrome: early experience and effectiveness. Acad Radiol 2010;17(05):603–606
17 Flagel BT, Luchette FA, Reed RL, et al. Half-a-dozen ribs: the breakpoint for mortality. Surgery 2005;138(04):717–723, discussion 723–725
18 Marasco S, Lee G, Summerhayes R, Fitzgerald M, Bailey M. Quality of life after major trauma with multiple rib fractures. Injury 2015;46(01):61–65
19 Finneran Iv JJ, Gabriel RA, Swisher MW, et al. Ultrasound-guided percutaneous intercostal nerve cryoneurolysis for analgesia following traumatic rib fracture -a case series. Korean J Anesthesiol 2020;73(05):455–459
20 Fokin AA, Steuerwald NM, Ahrens WA, Allen KE. Anatomical, histologic, and genetic characteristics of congenital chest wall deformities. Semin Thorac Cardiovasc Surg 2009;21(01):44–57
21 Keller BA, Kabagambe SK, Becker JC, et al. Intercostal nerve cryoablation versus thoracic epidural catheters for postoperative analgesia following pectus excavatum repair: preliminary outcomes in twenty-six cryoablation patients. J Pediatr Surg 2016;51(12):2033–2038
22 Harbaugh CM, Johnson KN, Kein CE, et al. Comparing outcomes with thoracic epidural and intercostal nerve cryoablation after Nuss procedure. J Surg Res 2018;231:217–223
23 Graves CE, Moyer J, Zobel MJ, et al. Intraoperative intercostal nerve cryoablation during the Nuss procedure reduces length of stay and opioid requirement: a randomized clinical trial. J Pediatr Surg 2019;54(11):2250–2256
24 Bittman RW, Peters GL, Newsome JM, et al. Percutaneous image-guided cryoneurolysis. AJR Am J Roentgenol 2018;210(02):454–465

This document was downloaded for personal use only. Unauthorized distribution is strictly prohibited.

 © 2022. Thieme. All rights reserved.